

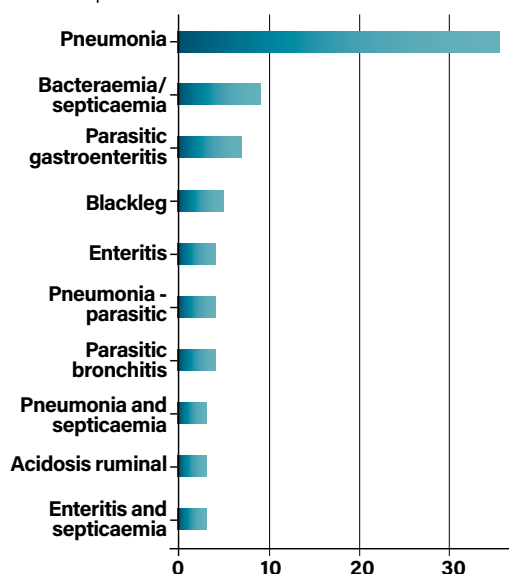
# Regional Veterinary Laboratories Report

September 2020

Regional Veterinary Laboratories (RVLs) carried out necropsy examinations on 473 carcasses and 54 fetuses during September 2020. Additionally, 1,571 diagnostic samples were tested to assist private veterinary practitioners (PVPs) with the diagnosis and control of disease in food-producing animals. This report describes a selection of cases investigated by the Department of Agriculture, Food and the Marine's (DAFM) veterinary laboratories in September 2020. The objective of this report is to provide feedback to veterinary practitioners on the pattern of disease syndromes at this time of the year by describing common and highlighting unusual cases. Moreover, we aim to assist with future diagnoses, encourage thorough investigations of clinical cases, highlight available laboratory diagnostic tools and provide a better context for practitioners when interpreting laboratory reports.

## CATTLE

Pneumonia and bacteraemia/septicaemia were the most common causes of death in bovine carcasses submitted to the RVLs in September 2020.



**Table 1: The most common causes of death diagnosed in bovine carcasses submitted to DAFM RVLs in September 2020.**

## GASTROINTESTINAL TRACT

### Umbilical hernia

A one-month-old Belgian Blue calf was submitted to Kilkenny RVL with a history of scour and dehydration. On examination, there was a strangulated umbilical hernia with intussusception of the herniated segment of intestine. *Escherichia coli* was cultured on multiple organs; tests for salmonella, bovine viral diarrhoea virus (BVDV) and coccidiosis were negative.

### Abomasitis

A five-month-old Limousin calf was submitted to Kilkenny RVL with a history of bloat and passing dark faeces. The calf had not responded to treatment with antibiotics and antispasmodics. The calf was severely dehydrated and there were multifocal fibrin strands in the peritoneum. There was a severe diffuse fibrino-necrotic ulcerative abomasitis with yellow exudates. *E. coli* was cultured from the abomasum and fluorescent antibody technique

(FAT) for *Clostridium sordellii* returned a positive result. A diagnosis of abomasitis was made; use of a multivalent clostridial vaccine was recommended.

### Parasitic gastroenteritis

A seven-month-old calf was submitted to Limerick RVL with a history of weakness and diarrhoea. It was noted to be small for its age and in extremely poor body condition. Necropsy disclosed severe oedema of the abomasal mucosa; scrapings from the mucosa disclosed multiple nematodes under microscopy. The intestinal mucosa was thickened and oedematous and there was a large volume of liquid intestinal contents. A McMaster's test on intestinal contents returned a faecal egg count of 1,150 eggs per gram (EPG). It was noted that the sample was extremely liquid, which can have the effect of artificially lowering egg counts, by dilution. The actual number of eggs in the intestinal contents of this animal may have been far higher. Histopathology disclosed abomasitis and enteritis, nematodes were observed in the abomasal mucosa and coccidial schizonts in the intestinal mucosa. A diagnosis of parasitic gastroenteritis was made.

### Ruminal acidosis

Athlone RVL examined two 30-month-old bullocks that had been found dead. There were two more very sick animals in the group and the remaining animals were less severely affected. There were similar findings in both carcasses. Preservation and body condition were good. The rumen contained a large amount of grain mixed with forage. Intestinal contents were light green/grey in colour with a lot of meal present. The pH of the rumen contents was 4.3 in one case and 4.4 in the other, which was considered indicative of ruminal acidosis. Histopathology showed vacuolation of the superficial epithelial layer and neutrophil infiltration consistent with a chemical rumenitis. A diagnosis of ruminal acidosis due to grain overload was made. It transpired that an on-farm error had resulted in the animals being overfed the previous evening.

### Hepatic lipidosis

A five-year-old cow was submitted to Athlone RVL with a history of having calved twins the day before. It was an

assisted delivery and an internal injury or haemorrhage related to the recent parturition was suspected. Carcase preservation and body condition were moderately good. The liver was enlarged, friable, greasy and orange with copious greasy fat oozing from the cut surface. There were retained foetal membranes in the uterus, but the uterine contents were not foul smelling and there was no evidence of trauma to the uterus or birth canal. The mammary glands, kidneys, lungs and gastrointestinal tract (GIT) were unremarkable. A diagnosis of 'fatty liver disease' or hepatic lipidosis was made. Hepatic lipidosis and associated metabolic disturbance may occur in the periparturient period. The twin pregnancy in this cow is likely to have been significant.

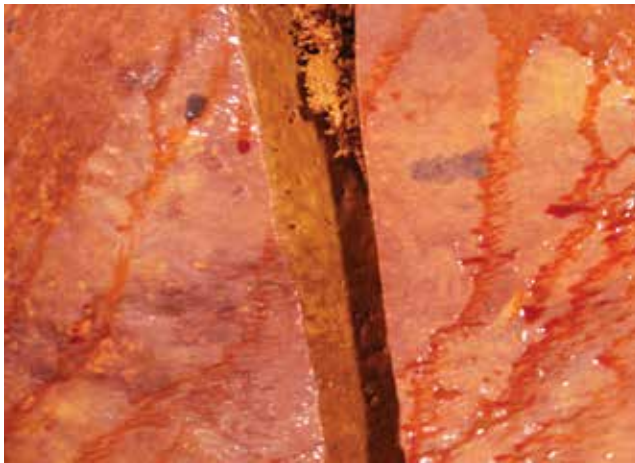


Figure 1: Hepatic lipidosis in a cow. Photo: Denise Murphy.

**RESPIRATORY TRACT**

**Parasitic bronchitis**

*Dictyocaulus viviparus* was detected in 47.5% of cases of bovine respiratory disease (BRD) diagnosed at necropsy in the RVLs during September 2020.

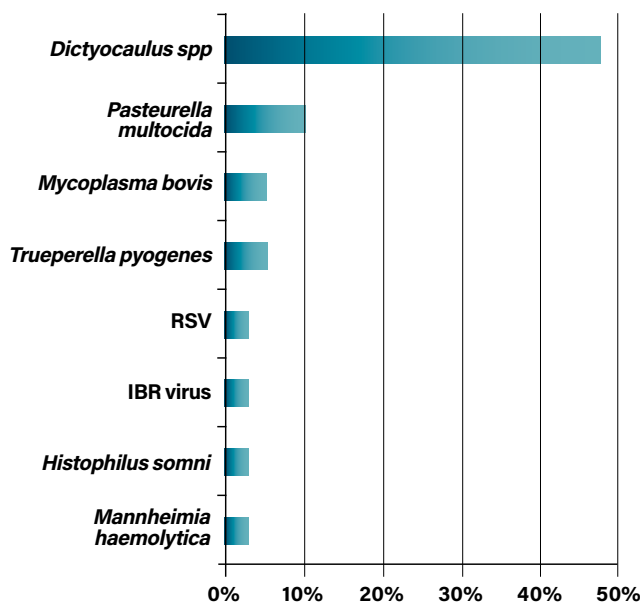


Table 2: The pathogens most commonly identified in cases of respiratory disease diagnosed at necropsy in the RVLs during September 2020.

Sligo RVL diagnosed parasitic pneumonia in several cases. In one of the cases, an 18-month-old heifer with severe clinical signs of pneumonia was submitted. Treatment had been unsuccessful. On post-mortem examination there was fibrinopurulent, frothy exudate containing *D. viviparus* nematodes in the airways. The lung presented with well-demarcated, cranio-ventral consolidation affecting 60% of the parenchyma. The mediastinal lymph nodes were enlarged. There was symmetrical ulceration of arytenoid cartilage of the larynx with haemorrhage and oedema present in the surrounding soft tissue. There was a focal chronic pericarditis approximately 2cm in diameter. Histopathology of the lung revealed severe, diffuse, necrotising broncho-interstitial pneumonia with hyaline membranes and type 2 pneumocyte hyperplasia. The cause of death in this animal was due to the severe subacute pneumonia. In this case, the parasitic pneumonia was exacerbated by a bacterial infection affecting a large portion of lung tissue. The lesion in the pericardium suggests a concurrent serositis spreading from the lung that may be associated with *Mannheimia spp.* and *Histophilus somni* infections. The pericardial lesion is likely to explain the severity of the clinical signs in this case and the lack of response to treatment. It was not possible to determine the duration of the pericarditis, but it may have been present subclinically for some time. Bacteriology and virology testing were unrewarding, which is not surprising considering the history of treatment. The lesions in the larynx were likely due to prolonged dyspnoea.

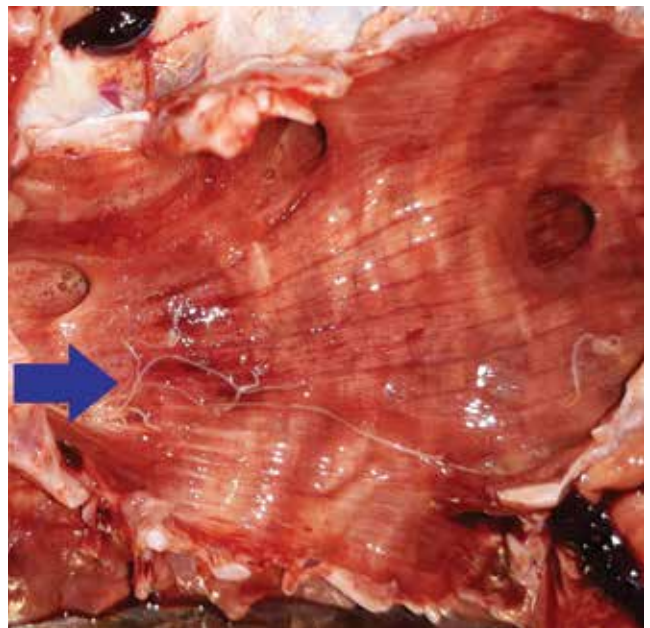


Figure 2: *Dictyocaulus viviparus* (arrow) in a bovine trachea. Photo: Rebecca Froehlich-Kelly.

A three-month-old calf was submitted to Limerick RVL with a history of coughing. Necropsy disclosed high numbers of lungworms in the trachea, many still alive, and consolidation of lung tissue with some emphysema in the caudal lung. The abomasal mucosa was nodular in appearance and mucosal scrapings contained multiple

## I REGIONAL VETERINARY LABORATORIES REPORT

nematodes upon microscopy. A McMaster's test on intestinal contents returned a faecal egg count of over 8,000 EPG. Histopathology disclosed broncho-interstitial pneumonia with lungworm larvae visible in the airways and abomasitis with nematodes visible in the abomasal mucosa. A diagnosis was made of parasitic bronchitis and parasitic gastro-enteritis; pneumonia was also present, most likely as a sequel to lungworm infection. It was recommended that parasite control measures in this herd should be reviewed without delay.

### Vena caval thrombosis

An eight-month-old bovine animal was submitted to Kilkenny RVL for necropsy. On gross examination, the lungs had a chequerboard appearance due to multifocal lobular consolidation. There was diffuse interlobular and intra-alveolar oedema and emphysema. There was hepatic abscessation adjacent to the vena cava. On histopathological examination of the lungs, multifocally large numbers of bacteria-filled blood vessels. In other blood vessels, suppurative thrombi were present, large numbers of neutrophils and fibrin expanded the alveolar walls. Diffuse interstitial pneumonia with septic emboli and vascular thrombosis of pulmonary vessels are consistent with hepatic abscessation and posterior vena caval thrombosis. A diagnosis of posterior vena cava thrombosis was made. A review of diet was recommended as ruminal acidosis may predispose to the formation of hepatic abscesses.

## URINARY/REPRODUCTIVE TRACT

### Nephritis

A five-month-old weanling was submitted to Kilkenny RVL with a history of bloat and haematuria. Findings upon post-mortem examination included marked dehydration and the kidneys had multifocal abscessation and multifocal infarcts bilaterally. There were approximately 20 litres of straw-coloured fluid with fibrin strands in the abdomen. There were multifocal fibrinous adhesions between intestinal segments and the mesenteric lymph nodes were enlarged. Histopathology of the kidney showed chronic active suppurative tubular interstitial nephritis. Examination of the intestine showed suppurative enteritis with bacterial colonies visible however autolysis impaired further interpretation. A diagnosis of nephritis and peritonitis was made. Culture results on the kidney and intestine were unrewarding likely due to the recent antibiotic treatment, and an underlying infectious agent was not identified.

## MUSCULOSKELETAL

### Clostridial disease

A six-month-old calf was submitted to Sligo RVL with a history of sudden death. There had been three further sudden deaths on farm in the previous days. Some foci in the superficial gluteal muscles were dry, but not discoloured. There was black and dark red, dry emphysematous myositis present in the ventral jaw musculature (musculus geniopharyngeus). *Clostridium septicum* was detected in the lesions by a fluorescent antibody test. Clostridial myositis

(malignant oedema) was diagnosed as the cause of death.

### Osteomyelitis

A 2.5-year-old cow was delivered to Sligo RVL with a history of ill thrift for two months, nasal discharge, coughing, frothing and panting. There was multifocal abscessation around the eyes, neck and jaw. On necropsy, there was focally extensive, necrotising and purulent cellulitis and abscesses involving the left side of the face and extending along the fascial planes from her mandible to her nose. There was necrosis and osteitis of the tympanic bulla and the surrounding bone. There was fibrino-purulent material present in the frontal sinuses. There was a diffuse fibrino-purulent meningitis. *Trueperella pyogenes* was cultured from the lesions. The lesions observed in this animal were very severe and consistent with the clinical signs described. The history of ill thrift is consistent with a bone infection involving the mandible and masticatory muscles which likely resulted in difficulty feeding. The meningitis was acute and explains the pain, distress and nervous signs described in terminal stages. All the lesions in this animal were related. The meningitis occurred as a result of local invasion by the infection into the cranial vault. The involvement of the tympanic bulla was considered significant as chronic otitis may have been the initial source – this may have been present from early life. Other possible differential diagnoses are chronic osteitis due to *Actinobacillus* spp. or *Actinomyces* spp., but the severity and aggressive spread of the infection is considered unusual. *Trueperella pyogenes* is a frequent secondary invader.

## CARDIOVASCULAR SYSTEM

### Omphalophlebitis

Athlone RVL examined a three-week-old suckler calf with a history of acute onset recumbency and open mouth breathing. The calf was treated but died a few hours later. Carcass preservation and body condition were good. The umbilicus was enlarged and there was an umbilical abscess extending along urachal vessels to the bladder. There was a mild fibrinous peritonitis and severe fibrinous pleuritis and pericarditis. *E. coli* was isolated from an umbilical swab. A diagnosis of omphalophlebitis with secondary polyserositis was made.

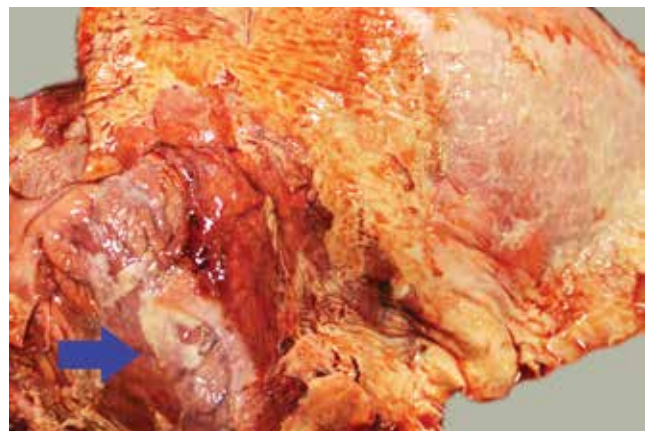
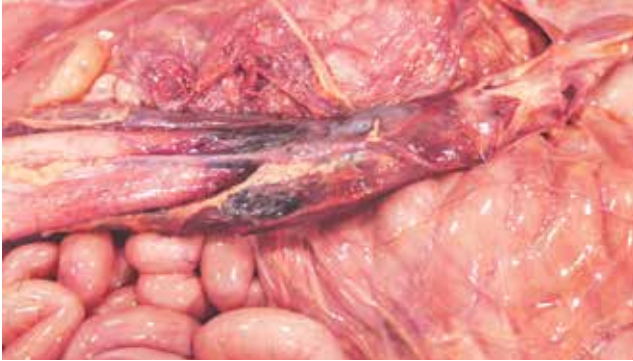

Figure 3: Pleurisy and pericarditis (arrow) in a calf secondary to omphalophlebitis. Photo: Denise Murphy.



Omphalophlebitis was also diagnosed at Athlone RVL in a bovine perinate that lived for ten hours. This was a heifer's calf and the birth had been unassisted. The calf stood and was seen suckling the dam but was found dead a few hours later. The carcass preservation was good. There was pustular necrotic material in the navel and the urachal vessels were dilated and inflamed and there was a mild fibrinous peritonitis.



**Figure 4: Omphalophlebitis in a 10-hour-old calf. Photo: Denise Murphy.**

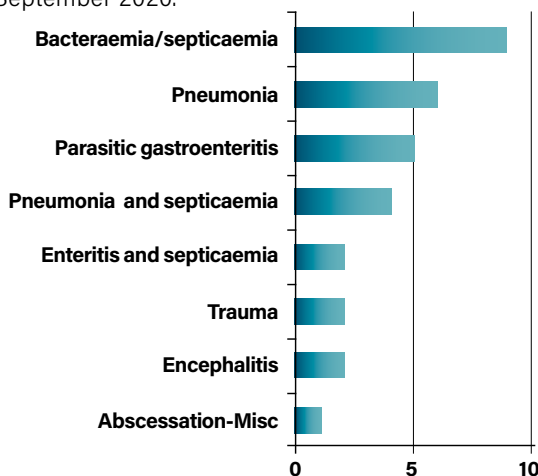
**MISCELLANEOUS**

**Sporadic lymphoma**

Biopsy samples were submitted to Kilkenny RVL from a cow with multiple raised cutaneous lesions. Histopathology of the section found, expanding the tissue a large, unencapsulated, infiltrative, densely cellular neoplasm composed of sheets of round cells on a moderate pre-existing collagenous stroma. Neoplastic cells had indistinct cell borders, a scant amount of eosinophilic cytoplasm, and round to ovoid nuclei with finely stippled chromatin and one to three variably distinct nucleoli. The mitotic count averaged two per field at high power (x40) magnification. There were reactive lymphocytes and foci of necrosis. A diagnosis of lymphoma was reached. Blood from the animal returned a negative result to serology for enzootic bovine leukosis (EBL). Bovine lymphoma is classified as sporadic or associated with EBL.

**SHEEP**

Bacteraemia/septicaemia and pneumonia were the most commonly recorded causes of death in sheep carcasses submitted to the regional veterinary laboratories in September 2020.



**Table 3: The most common causes of death in ovine carcasses (excluding foetuses) submitted to DAFM RVLs in Sept. 2020.**

**FEATURED TOPIC: HISTOMONIASIS IN TURKEYS**

The protozoan parasite *Histomonas meleagridis* causes histomoniasis, also known as blackhead disease. *H. meleagridis* is typically transmitted in the egg of the caecal nematode, *Heterakis gallinarum*. Gallinaceous birds, including chickens, act as a reservoir for *H. gallinarum*.

Infected *H. gallinarum* eggs can remain viable in the environment for years. As chickens, partridges, and pheasants commonly have *H. gallinarum* in their intestines, they often are the source of the protozoal infection for other birds. Earthworms can also act as hosts for both parasites. Chickens and turkeys that ingest these earthworms can become infected. Transmission can occur in turkeys by direct cloacal contact with infected birds or via fresh droppings.

The condition is highly fatal in turkeys, but outbreaks can occur in chickens. The symptoms include depression, reduced appetite, poor growth, increased thirst, sulphur-yellow diarrhoea, listlessness, drooping wings, and unkempt feathers. Signs typically appear within seven to 12 days after infection.

The primary lesions of histomoniasis are in the caeca where there is inflammation and development of a yellowish green caseous exudate or, in later stages, a dry, cheesy core in the intestinal lumen. Liver lesions are variable in appearance and may be up to 4cm in diameter and involve the entire organ. The liver lesions must be differentiated from other agents including tuberculosis and leukosis.

No treatments are available for the condition. Prevention involves not rearing turkeys with chickens. Because *H. gallinarum* ova can survive in the soil for years, turkeys should not be put on ground contaminated by chickens.

**GASTROINTESTINAL TRACT**

**Ruminal acidosis**

Sligo RVL received a six-month old lamb which had been found dead approximately a week after being housed for fattening. There was one further sudden death in the group. On post-mortem examination the rumen contents appeared soft and of porridge-like consistency with a distinct odour. There were no intestinal contents. Ruminal pH value was 5.1. As post-mortem ruminal pH values below 5.5 are considered indicative of acidosis, ruminal acidosis was diagnosed as most likely cause of death. History provided also supported this diagnosis. A review of feeding management was recommended to the PVP and farmer.

**RESPIRATORY TRACT**

**Pneumonia**

Athlone examined an eight-month-old lamb with a history of dullness and being unsteady on its feet. It had been purchased one month previously. Carcass preservation and body condition were moderate. There

was an ulcerative oesophagitis in the proximal third of the oesophagus. There was diffuse pulmonary congestion and pinpoint black foci in the left lung lobes and a single 2-3mm black lesion in the left middle lobe. The liver was autolysed, but tiny pinpoint white foci were evident at the thin end. There were petechial haemorrhages in the swollen spleen. A strong positive result to a polymerase chain reaction (PCR) test for *Bibersteinia trehalosi* was returned from the lungs. Histopathology of the lung and liver showed scattered multifocal areas of necrosis and bacterial colonies with aggregates of streaming 'oat cells' and leucocytes consistent with pasteurellosis. A diagnosis of systemic infection caused by *Bibersteinia trehalosi* was made.

### ***Bibersteinia trehalosi***

*Bibersteinia trehalosi* is closely related to *Mannheimia haemolytica* and has a similar pathogenesis and requires similar methods for treatment and control. Some vaccine data sheets may refer to this pathogen by its previous name, *Pasteurella trehalosi*.

Two four-month-old lambs with a history of swollen heads and difficulty in feeding and walking were submitted to Sligo RVL. On post-mortem examination, there was extensive oedema around the head, oesophagus and pharynx. There was pleurisy and cranio-ventral consolidation of lungs bilaterally affecting approximately 50% of the pulmonary parenchyma. The liver appeared jaundiced. *Mannheimia haemolytica* was detected in lung parenchyma. On histopathology, there was diffuse, acute, severe, necrotising, suppurative pneumonia in sections from consolidated areas. Pneumonia with likely sepsis were diagnosed as cause of death. The jaundiced liver indicates hepatic damage explaining the observed oedema.

### **Traumatic pharyngitis**

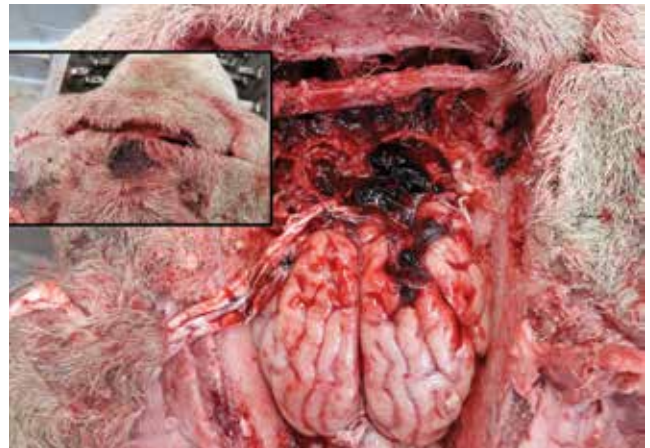Sligo RVL received a three-year-old ewe which had been 'failing' for the previous two weeks and appeared to have a problem in the throat area. The farmer reported further similar deaths in the same group. On post-mortem examination there was a focally extensive area of bruising and haemorrhage under the jaw and distal pharynx. Granulation tissue was present in a focal area of the distal pharynx. The nasal mucosa was congested and contained large blood clots. There was a large amount of blood in the rumen. Traumatic pharyngitis resulting in haemorrhage and obstruction of nasal passages was diagnosed as the most likely cause of death. The only potential source of the substantial haemorrhage found was the small area of damage in the distal pharynx. However, the haemorrhage seemed to originate from a partially healed lesion likely developed some time ago. Injuries such as this are usually associated with recent dosing, but there was no recent dosing reported in the history of this case. It was noted

that this was the second ewe affected with similar signs which would be unusual. The herdowner was advised that sources of trauma around feeders or fences should also be considered. Other differentials for this condition are rare.

## MISCELLANEOUS

### **Trauma**

Sligo RVL received a 1.5-year-old ram that had been found recumbent and dyspnoeic before death. Externally an older abrasion approximately 3cm in diameter was noted on the forehead. On opening of the skull, there was extensive cerebral haemorrhage in the frontal area of the cranial vault underneath the observed lesion. There was a bone fragment loose and impressed into the rostral cerebrum. Brain haemorrhage most likely caused by trauma and skull fracture was diagnosed as cause of death. Rams are prone to fighting injuries around the skull which is the most likely cause of this trauma.



**Figure 5: Frontal cerebral haemorrhage caused by traumatic injury in a ram. The animal had an external chronic wound on the forehead (inset). Photo: Rebecca Froehlich-Kelly.**

## PIGS

### **CARDIOVASCULAR SYSTEM**

#### **Vegetative endocarditis**

A late-stage fattener pig was submitted to Dublin RVL with a history of respiratory signs. Necropsy detailed a carcass in excellent body condition in a state of very poor preservation. Extending along the left atrioventricular (AV) valve leaflets on the heart were numerous white to cream, multifocal vegetative masses about 1cm in size. There was a severe diffuse fibrinous pericarditis and a focal area of fibrinous pleuritis affecting the mid ventral portion of the right lung. There were multiple foci of interlobular oedema of the left lung with interlobar soft adhesions. A low volume cream to yellow turbid effusion was present in the left stifle. *Erysipelothrix rhusiopathiae* was cultured from the left stifle, pericardium and heart valve; *Pasteurella multocida* was isolated from the lung tissue. Histopathology disclosed valvular vegetative endocarditis with intralesional bacterial colonies and a marked diffuse interstitial pneumonia with occasional thrombi. Numerous alveoli contained multiple macrophages which were occasionally haemosiderin-laden ('heart failure cells').

Clinically, erysipelas can occur as a subclinical infection or present in acute or chronic forms. Clinical presentations in acute disease can include pyrexia, respiratory signs and sudden death. Other signs include reddening or cyanosis of the skin of the ears, snout, pharyngeal area and lower abdomen extending to diamond skin (rhomboid urticaria) lesions. Acute and chronic forms of the disease can occur concurrently or sequentially on farm. Chronic erysipelas can present as arthritis/polyarthritis and lameness. An additional presentation can include vegetative endocarditis.

#### **'Heart failure cells'**

As a result of passive congestion and dilated capillaries, red blood cells can leak into alveolar spaces and are broken down releasing haemoglobin. When haemoglobin is phagocytosed by the alveolar macrophages it is broken down to haemosiderin and biliverdin. The haemosiderin accumulates as a golden-brown pigment. These pigment-rich macrophages can be seen on histopathology in heart failure and have been referred to as 'heart failure cells.'